



Photic Head Shaking*

» **Bonnie R. Rush, DVM, MS, DACVIM**

» **Jason A. Grady, DVM, MS, DACVIM**

Kansas State University

Head shaking is a behavior in which horses toss their heads, rub their noses, snort, and/or sneeze in the absence of obvious external stimuli. Some horses head shake with such violence that they are dangerous to the handler or rider.

In a 1987 review of 100 head shaking horses, the cause was undetermined in nearly 90% of cases. In 1995, Madigan and coworkers presented a series of seven cases in which head shaking was triggered by natural sunlight, and darkness provided relief from the condition; this disorder is called *photic head shaking*. Photic head shaking horses are suspected to experience a burning sensation or tingling of the muzzle (neuropathic pain) in response to bright sunlight.

The mechanism of photic head shaking may be similar to photic sneezing in humans, in which exposure to bright light triggers sneezing episodes. Photic sneezing in humans is a heritable, nonallergic disorder. Photic head shaking may represent a form of referred pain in which stimulation of one of the cranial nerves enhances irritability of the other—in this instance, optic-trigeminal summation. This may be associated with convergence between optic and trigeminal tracts in the brainstem. Therefore, neuropathic pain is the most plausible explanation for the signs associated with photic head shaking.

Bright sunlight is the most common trigger for neuropathic head shakers, but other stimuli, including specific feeds (as in gustatory head shaking), may also serve as a trigger for infraorbital nerve irritability. Therefore, disorders other than neuropathic pain should be evaluated to eliminate other causes of this behavior. In some horses, the triggering stimulus cannot be identified; however, the head shaking seems to be characteristic of neuropathic pain, and affected patients respond to medical therapy.

Diagnostic Criteria Historical Information

► The condition affects adult horses. The mean age of onset is 7.5 to 9.2 years. However, it has been documented in horses younger than 5 years.

At a Glance

► **Diagnostic Criteria**

Page 327

► **Treatment Recommendations**

Page 329

► **Differential Diagnosis**

Page 330

► **Prognosis**

Page 331

TO LEARN MORE



► **Understanding Behavior: Head Shaking (November/December 2008)**

► To see a video of a horse with head shaking, go to the Web exclusives at **CompendiumEquine.com**

Related content on
CompendiumEquine.com

*Updated by the authors and reprinted with permission from *Standards of Care: Equine Diagnosis and Treatment* 2001;1.1:1-4.

FIGURE 1



A commercial mask with protective lenses.

Critical Point

Horses may not exhibit the behavior during the examination; therefore, the owner should be asked to make a videotape of the head shaking before the appointment.

- ▶ No breed predilection.
- ▶ Geldings are overrepresented. Affected mares should be evaluated for ovarian dysfunction. The absence of testicular or ovarian hormones may play a role in the pathophysiology.
- ▶ Clinical signs are often seasonal, abating during the winter and returning in the spring.
- ▶ The behavior is exhibited at rest and during exercise. Violent head shaking is common at the beginning of exercise.
- ▶ Affected horses attempt to avoid direct sunlight by seeking shade or hiding their heads in unusual places.
- ▶ Photic head shaking may begin after an upper respiratory tract infection.
- ▶ Horses may not exhibit the behavior during the examination; therefore, the owner should be asked to make a videotape of the head shaking before the appointment.

Physical Examination Findings

- ▶ Sudden, violent, jerking movements of the head in the absence of obvious external stimuli.
- ▶ Characteristic quick vertical flips or jerking movements (as if stung by a bee on the end of the nose) may be interspersed with horizontal and rotary activity.
- ▶ Affected horses often snort, sneeze, and rub their noses.
- ▶ Ophthalmic, otic, and oral examinations should be performed to rule out other causes of head shaking.

- ▶ Findings are unremarkable in photic head shakers.
- ▶ Horses with head shaking due to causes other than sunlight usually demonstrate intentional head tossing rather than rapid, vertical flips that resemble a reaction to a bee sting.

Laboratory Findings

- ▶ Complete blood count and serum chemistry analysis findings are unremarkable.
- ▶ Endoscopic examination of the upper respiratory tract (including guttural pouches) and radiographic examination of the skull should be performed in all horses with head shaking to rule out temporohyoid osteoarthropathy, a foreign body, or traumatic injury. The results are unremarkable in horses with photic head shaking.

Other Significant Diagnostic Findings

- ▶ To determine whether the behavior is induced by natural light, ideally, the clinician should subject the horse to the following: direct sunlight, blindfolding, the outdoors at night, and the application of dark eye lenses (**FIGURE 1**) in direct sunlight. The cessation of clinical signs during protection from direct

FIGURE 2

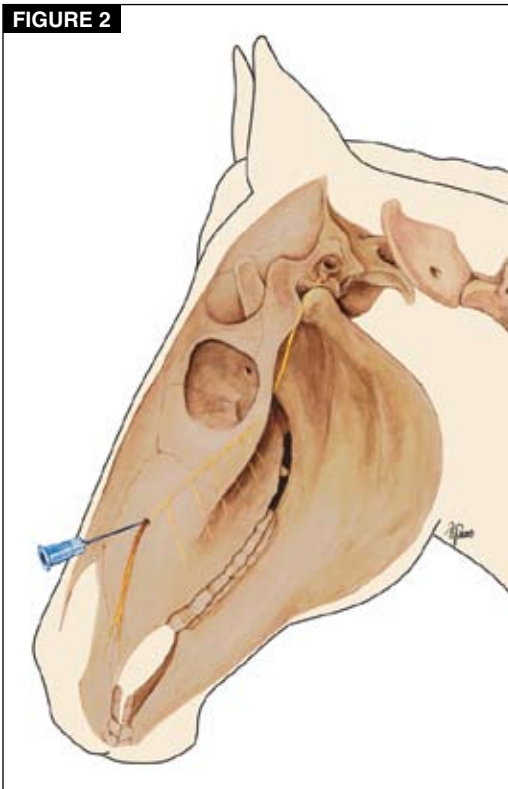


Illustration by Felecia Paras

Infraorbital nerve block.

sunlight indicates that light is a stimulus for head shaking.

- ▶ Bilateral infraorbital nerve block (**FIGURE 2**; 10 mL of mepivacaine over and within the infraorbital canal) should be performed in horses with characteristic head shaking that does not respond to medical management. If nerve block results in the abatement of clinical signs, the diagnosis is confirmed.
- ▶ Bilateral posterior ethmoidal nerve block (**FIGURE 3**; 5 mL of mepivacaine) using a 7-cm, 19-gauge spinal needle: the needle is inserted below the zygomatic arch and directed rostrally and ventrally toward the upper sixth cheek tooth (approximately 5 cm; **FIGURE 4**).

Differential Diagnosis

See **BOX 1**.

Summary of Diagnostic Criteria for Photic Head Shaking

- ▶ Negative findings from otic, ophthalmic, oral, endoscopic (the upper airway, including the guttural pouches), and radiographic (skull) examinations.
- ▶ Demonstration of sunlight-induced head shaking (sunlight may not be the only trigger for neuropathic head shaking).
- ▶ Favorable response to a 7-day course of cyproheptadine and/or carbamazepine (see below).

FIGURE 3

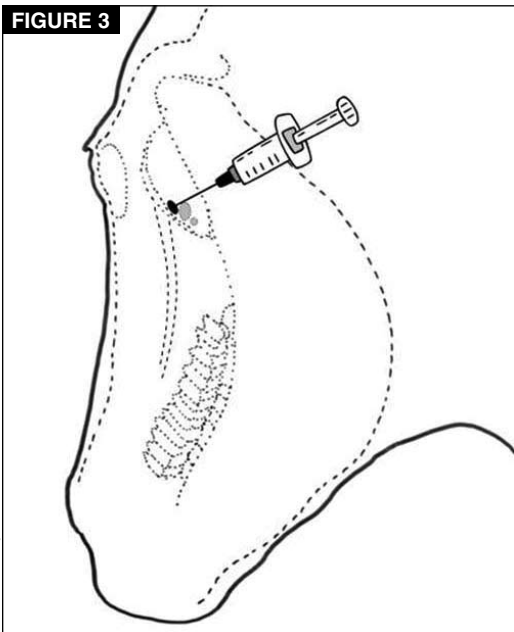


Illustration by Mal Rooks Hoover

Diagram of the landmarks for a posterior ethmoidal nerve block.

- ▶ Favorable response to bilateral infraorbital or posterior ethmoidal nerve block in horses that do not respond to cyproheptadine.

Treatment Recommendations

Medical Therapy

Cyproheptadine

- ▶ Cyproheptadine is an antihistamine and serotonin antagonist with anticholinergic effects. The mechanism of action of cyproheptadine in treating photic head shaking is unknown.
- ▶ Administer a 7-day course of cyproheptadine (0.3–0.6 mg/kg PO q12h) to determine response to therapy.
- ▶ Horses that respond favorably should be treated with cyproheptadine during the season in which they exhibit head shaking.
- ▶ Adverse effects include transient lethargy, depression, or anorexia.

Carbamazepine

- ▶ Carbamazepine (3–4 mg/kg PO q6–8h), which is labeled for treating trigeminal neuralgia in humans, may be administered alone or with cyproheptadine in horses that fail to respond to cyproheptadine alone.

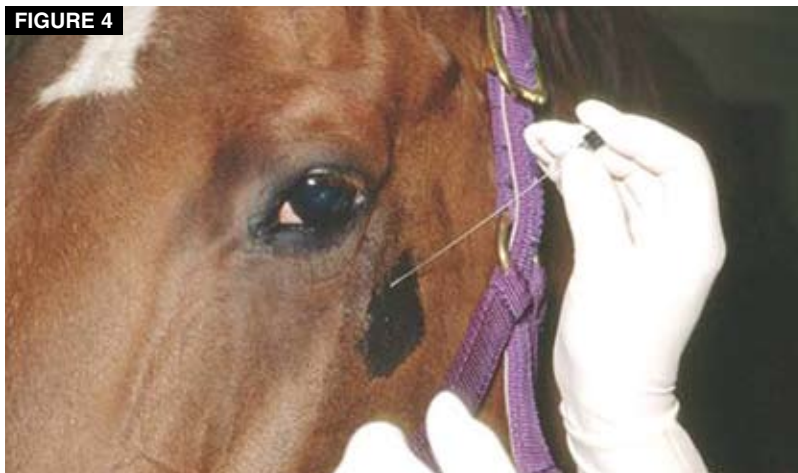Melatonin

- ▶ Melatonin (15–18 mg PO q24h administered between 5:00 and 6:00 PM) has reduced clinical signs in some horses.

Topical EMLA Cream

- ▶ Topical EMLA cream (AstraZeneca; lidocaine 2.5% and prilocaine 2.5%) may provide

FIGURE 4



Posterior ethmoidal nerve block. A 7-cm, 19-gauge spinal needle is inserted below the zygomatic arch and directed rostrally and ventrally toward the upper sixth cheek tooth.

Critical Point

Approximately 70% to 80% of photic head shakers respond favorably to cyproheptadine. Some horses may respond initially but become more resistant to therapy.

Differential Diagnosis

BOX 1

- ▶ **Temporohyoid osteoarthropathy:**
 - ▶ **Proliferation of the stylohyoid bone**—perform an endoscopic examination of the upper airway that includes the guttural pouches.
 - ▶ **Osteitis of the petrous temporal bone**—perform a radiographic examination.
- ▶ **Foreign body, parasite, or infection in the external auditory canal**—perform an otoscopic examination.
- ▶ **Oral pain (wolf teeth or diastema), oral ulceration, periodontal disease, periapical abscess**—perform oral and radiographic examinations.
- ▶ **Iris cysts, uveitis, photophobia, retinal lesions**—perform an ophthalmic examination.
- ▶ **Miscellaneous conditions:**
 - ▶ **Guttural pouch mycosis, epiglottic entrapment**—perform an endoscopic examination.
 - ▶ **Cervical pain**—perform a radiographic examination of the cervical vertebrae.
 - ▶ ***Trombicula autumnalis* larval infestation (chiggers) of the muzzle**—perform a skin scrape.

Critical Point

If sunlight has been identified as the stimulus of infraorbital pain, reduced sunlight exposure is indicated for untreated horses or horses that do not respond to medical or surgical management.

transient relief when applied to the muzzle. Cover area with plastic wrap (make holes for nostrils). Leave on for 45 minutes.

Combination Treatment

- ▶ Cyproheptadine (as described above).
- ▶ Magnesium supplementation (Quiessence, Foxden Equine, Stuarts Draft, VA).
 - ▶ Increases threshold for nerve depolarization and may reduce irritability of trigeminal nerve.
 - ▶ Administer 2 oz q24h PO.
 - ▶ Increase to 4 oz q24h PO if no improvement.
 - ▶ Evaluate serum magnesium after 2 wk, then once monthly.
- ▶ Spirulina Wafers (Springtime, Inc, Cockeysville, MD).
 - ▶ The mechanism is unknown, but they may increase the threshold for nerve depolarization and decrease irritability of the trigeminal nerve.

Mechanical Techniques

- ▶ **The use of a full-face net (covers ears to muzzle) or fly fringe or netting over the muzzle** has reportedly been effective in controlling signs of head shaking. It is believed that the net or fringe over the muzzle provides a counterstimulant that may reduce responsiveness of the trigeminal nerve through receptor inhibition or adaptation.
- ▶ A commercial face mask with eye protection can be applied to control clinical signs when the horse is saddled or turned out during daylight (**FIGURE 1**).

Surgical Intervention

- ▶ **Bilateral infraorbital neurectomy** is a salvage procedure for cases refractory to medical therapy. Surgical candidates must demonstrate a consistent response to serial infraorbital nerve blocks. Infraorbital neurectomy has been shown to be effective in eliminating signs of head shaking. However, clinical improvement is inconsistent and often only temporary. Postoperative complications may include nasal pruritus (common, temporary), reinnervation, and neuroma formation.
- ▶ **Bilateral sclerosis of the posterior ethmoidal branch of the trigeminal nerve** is induced via perineural injection (5 mL) of 10% phenol in almond oil. In an anesthetized patient, insert a 20-cm stylet needle into the infraorbital canal to the level of the maxillary foramen; confirm needle location by fluoroscopy.
- ▶ In a recent study on **caudal compression of the infraorbital nerve** in 24 horses, 16 of 19 horses had a successful outcome.¹ The procedure requires specialized equipment, and the authors report that the technique needs refinement.

Patient Monitoring

- ▶ Horses should respond to cyproheptadine within 7 days.
- ▶ If head shaking is well controlled, the dose of cyproheptadine may be decreased to 0.12 mg/kg PO q12h.
- ▶ In many cases, medication may be discontinued during the winter.

Farm Management

- ▶ If sunlight has been identified as the stimulus of infraorbital pain, reduced sunlight

exposure is indicated for untreated horses or horses that do not respond to medical or surgical management. Affected horses can be turned out at night or during overcast days. If turned out during full sunlight, affected horses should have protection from the sun via a three-sided shed, trees, or a commercial face mask that provides eye protection.

Milestones/Recovery Time Frames

Cyproheptadine

- ▶ Approximately 70% to 80% of photic head shakers respond favorably to cyproheptadine. Some horses may respond initially but become more resistant to therapy.
- ▶ More than 80% of horses respond favorably to carbamazepine alone or in combination with cyproheptadine.
- ▶ Relief from head shaking may be observed within 48 hours of initiation of therapy.
- ▶ Clinical signs typically recur 24 hours after discontinuation of medical therapy.

Bilateral Infraorbital Neurectomy

- ▶ Approximately 30% to 40% of photic head shakers improve after this procedure.
- ▶ Careful case selection (consistent response to infraorbital nerve block) may increase the likelihood of a positive postoperative outcome.

Nose Net

- ▶ Clinical signs of head shaking completely resolve in 25% to 30% of horses with the use of a nose fringe or netting that applies pressure to the skin over the muzzle.

Treatment Contraindications

- ▶ Administration of antihistamines, corticosteroids, or NSAIDs is unrewarding.
- ▶ Intradermal skin testing followed by allergen-specific hyposensitization therapy is unsuccessful.

Prognosis

Favorable Criteria

- ▶ Response to cyproheptadine within the first 7 days of treatment.

Unfavorable Criteria

- ▶ Failure to respond to recommended therapies. 🐾

Reference

1. Roberts VL, McKane SA, Williams A, Knottenbelt DC. Caudal compression of the infraorbital nerve: a novel surgical technique for treatment of idiopathic headshaking and assessment of its efficacy in 24 horses. *Equine Vet J* 2009;41(2):165-170.

Recommended Reading

- ▶ **Cook WR.** Head shaking in horses: an afterword. *Compend Contin Educ Pract Vet* 1992;14:1369-1372.
- ▶ **Lane JG, Mair TS.** Observations on headshaking in the horse. *Equine Vet J* 1987;19:331-336.
- ▶ **Madigan JE.** In: Smith BP, ed. *Large Animal Internal Medicine*, 4th ed. St. Louis: Mosby; 2009:1044-1045.
- ▶ **Madigan JE, Bell SA.** Characterisation of headshaking syndrome—31 cases. *Equine Vet J Suppl* 1998;27:28-29.
- ▶ **Madigan JE, Bell SA.** Owner survey of headshaking in horses. *JAVMA* 2001;219(3):334-337.
- ▶ **Madigan JE, Kortz G, Murphy C, Rodger L.** Photic headshaking in the horse: 7 cases. *Equine Vet J* 1995;27:305-311.
- ▶ **Mair TS.** Assessment of bilateral infraorbital nerve blockade and bilateral infraorbital neurectomy in the investigation and treatment of idiopathic headshaking. *Equine Vet J* 1999;31:262-264.
- ▶ **Mair TS.** Headshaking associated with *Trombicula autumnalis* larval infestation in two horses. *Equine Vet J* 1994;26:244-245.
- ▶ **Mair TS, Howarth S, Lane JG.** Evaluation of some prophylactic therapies for the idiopathic headshaker syndrome. *Equine Vet J Suppl* 1992;11:10-12.
- ▶ **Mills DS, Cook S, Jones B.** Reported response to treatment among 245 cases of equine headshaking. *Vet Rec* 2002;150:311-313.
- ▶ **Mills DS, Cook S, Taylor K, Jones B.** Analysis of the variations in clinical signs shown by 254 cases of equine headshaking. *Vet Rec* 2002;150(8):236-240.
- ▶ **Mills DS, Taylor K.** Field study of the efficacy of three types of nose net for the treatment of headshaking in horses. *Vet Rec* 2003;152(2):41-44.
- ▶ **Newton SA, Knottenbelt DC, Eldridge PR.** Headshaking in horses: possible aetiopathogenesis suggested by the results of diagnostic tests and several treatment regimens used in 20 cases. *Equine Vet J* 2000;32:208-216.
- ▶ **Wilkins PA.** Cyproheptadine: medical treatment for photic headshakers. *Compend Contin Educ Pract Vet* 1997;19:98-111.

Did You Know?

- ▶ Infraorbital neurectomy was one of the earliest treatments for head shaking.^a

^aWilliams WL. Involuntary shaking of the head and its treatment by trifacial neurectomy. *Am Vet Rec* 1899;23:321-326.

CriticalPoint

More than 80% of horses respond favorably to carbamazepine alone or in combination with cyproheptadine.